

New Approaches to the Surgical Management of Hypertrophic Obstructive Cardiomyopathy

Ralph J. Damiano Jr., MD

Evarts A. Graham Professor of Surgery

Chief of Cardiothoracic Surgery

Co-Chair, Heart & Vascular Center

Barnes-Jewish Hospital

Washington University School of Medicine

St. Louis, MO

Washington University and Barnes-Jewish Heart & Vascular Center

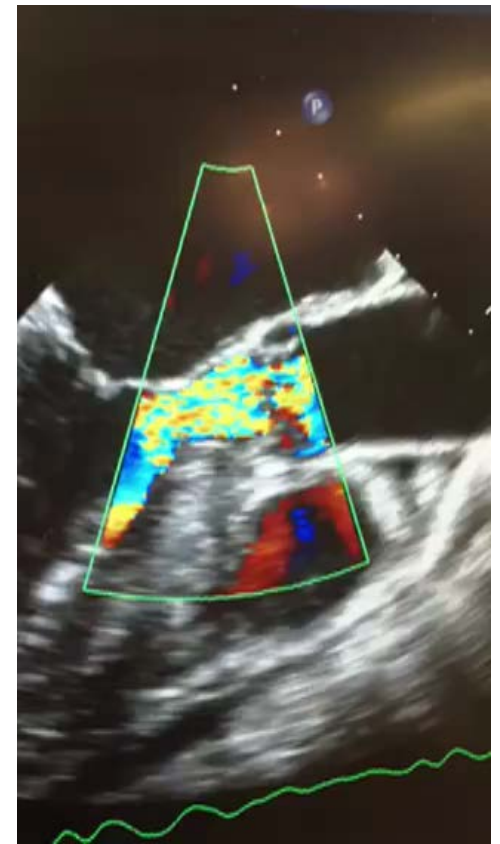
New Approaches to the Surgical Management of Hypertrophic Obstructive Cardiomyopathy

- Minimally invasive septal myectomy
- Surgical treatment of concomitant AF
- Surgical approaches to address residual mitral regurgitation

Surgical Management of HOCM

Indications for Ablation or Surgery

- Symptoms refractory to medical management
- LVOT obstruction ≥ 50 mmHg at rest or with physiological provocation



2014 ESC Guidelines on diagnosis and management of hypertrophic cardiomyopathy

The Task Force for the Diagnosis and Management of Hypertrophic Cardiomyopathy of the European Society of Cardiology (ESC)

Authors/Task Force members: Perry M. Elliott* (Chairperson) (UK) **Aris Anastasakis** (Greece), **Michael A. Borger** (Germany), **Martin Borggrefe** (Germany), **Franco Cecchi** (Italy), **Philippe Charron** (France), **Albert Alain Hagege** (France), **Antoine Lafont** (France), **Giuseppe Limongelli** (Italy), **Heiko Mahrholdt** (Germany), **William J. McKenna** (UK), **Jens Mogensen** (Denmark), **Petros Nihoyannopoulos** (UK), **Stefano Nistri** (Italy), **Petronella G. Pieper** (Netherlands), **Burkert Pieske** (Austria), **Claudio Rapezzi** (Italy), **Frans H. Rutten** (Netherlands), **Christoph Tillmanns** (Germany), **Hugh Watkins** (UK).

Additional Contributor: Constantinos O'Mahony (UK).

ESC Committee for Practice Guidelines (CPG): Jose Luis Zamorano (Chairperson) (Spain), **Stephan Achenbach** (Germany), **Helmut Baumgartner** (Germany), **Jeroen J. Bax** (Netherlands), **Héctor Bueno** (Spain), **Veronica Dean** (France), **Christi Deaton** (UK), **Çetin Erol** (Turkey), **Robert Fagard** (Belgium), **Roberto Ferrari** (Italy), **David Hasdai** (Israel), **Arno W. Hoes** (Netherlands), **Paulus Kirchhof** (Germany/UK), **Juhani Knuuti** (Finland), **Philippe Kolh** (Belgium), **Patrizio Lancellotti** (Belgium), **Ales Linhart** (Czech Republic), **Petros Nihoyannopoulos** (UK), **Massimo F. Piepoli** (Italy), **Piotr Ponikowski** (Poland), **Per Anton Sirnes** (Norway), **Juan Luis Tamargo** (Spain), **Michal Tendera** (Poland), **Adam Torbicki** (Poland), **William Wijns** (Belgium), **Stephan Windecker** (Switzerland).

Document Reviewers: David Hasdai (Israel) (CPG Review Coordinator), **Piotr Ponikowski** (Poland) (CPG Review Coordinator), **Stephan Achenbach** (Germany), **Fernando Alfonso** (Spain), **Cristina Basso** (Italy), **Nuno Miguel Cardim** (Portugal), **Juan Ramón Gimeno** (Spain), **Stephane Heymans** (Netherlands), **Per Johan Holm** (Sweden), **Andre Keren**

Recommendations on Septal Reduction Therapy

RECOMMENDATION	CLASS OF REC.	LEVEL OF EVIDENCE
It is recommended that septal reduction therapies be performed by experienced operators, working as part of a multidisciplinary team expert in the management of HCM.	I	C
Septal reduction therapy to improve symptoms is recommended in patients with a resting or maximum provoked LVOTO gradient of ≥ 50 mmHg, who are in NYHA functional Class III-IV, despite maximum tolerated medical therapy.	I	B

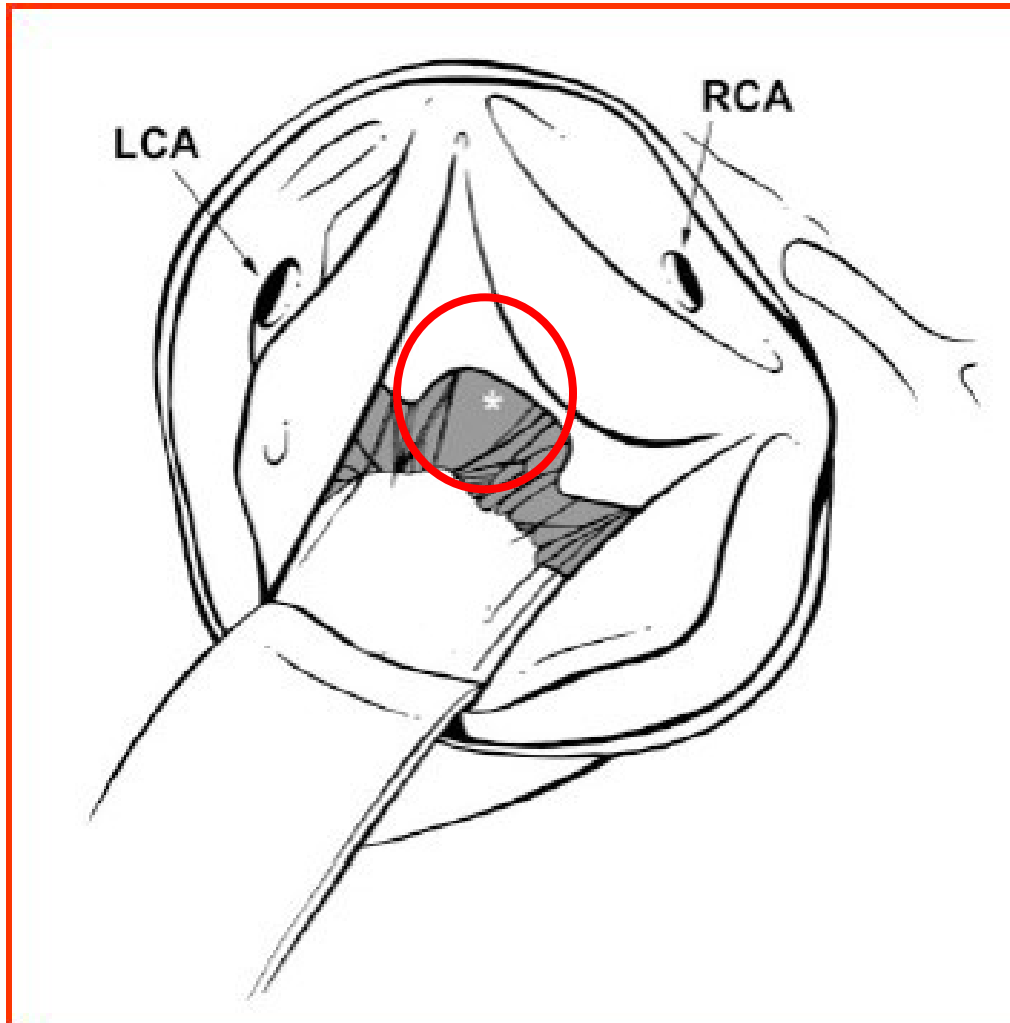
**HCM = hypertrophic cardiomyopathy; LVOTO = left ventricular outflow tract obstruction;
NYHA = New York Heart Association**

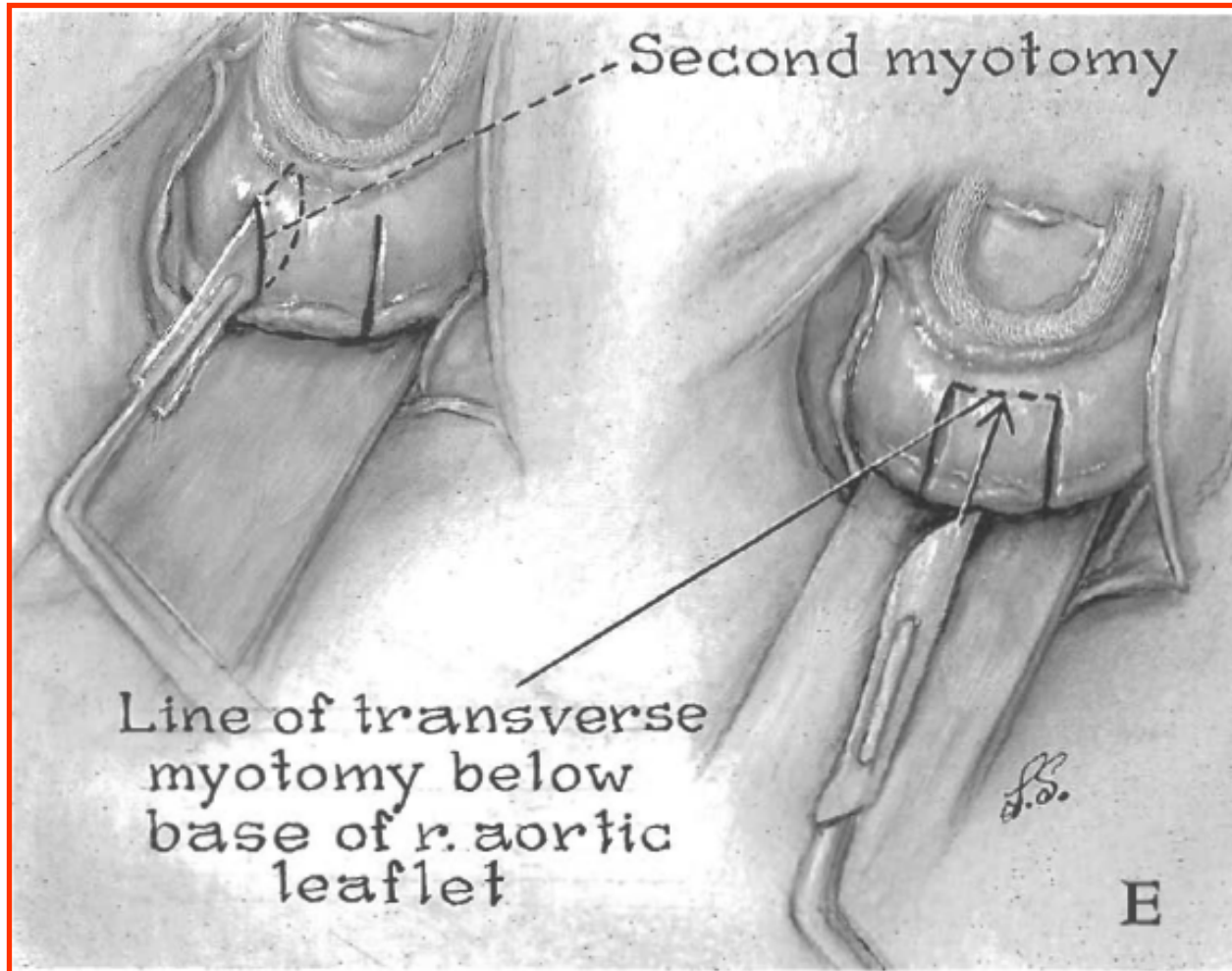
Surgical Management of HOCM

History

- Septal myectomy introduced by Morrow at NIH in 1961
- Modified to extend further into ventricular cavity and to divide aberrant mitral chordal attachments and atypical insertions of the papillary muscles
- A historical approach was to perform mitral valve replacement but this has been rightfully abandoned in centers of excellence.

Surgical Approach



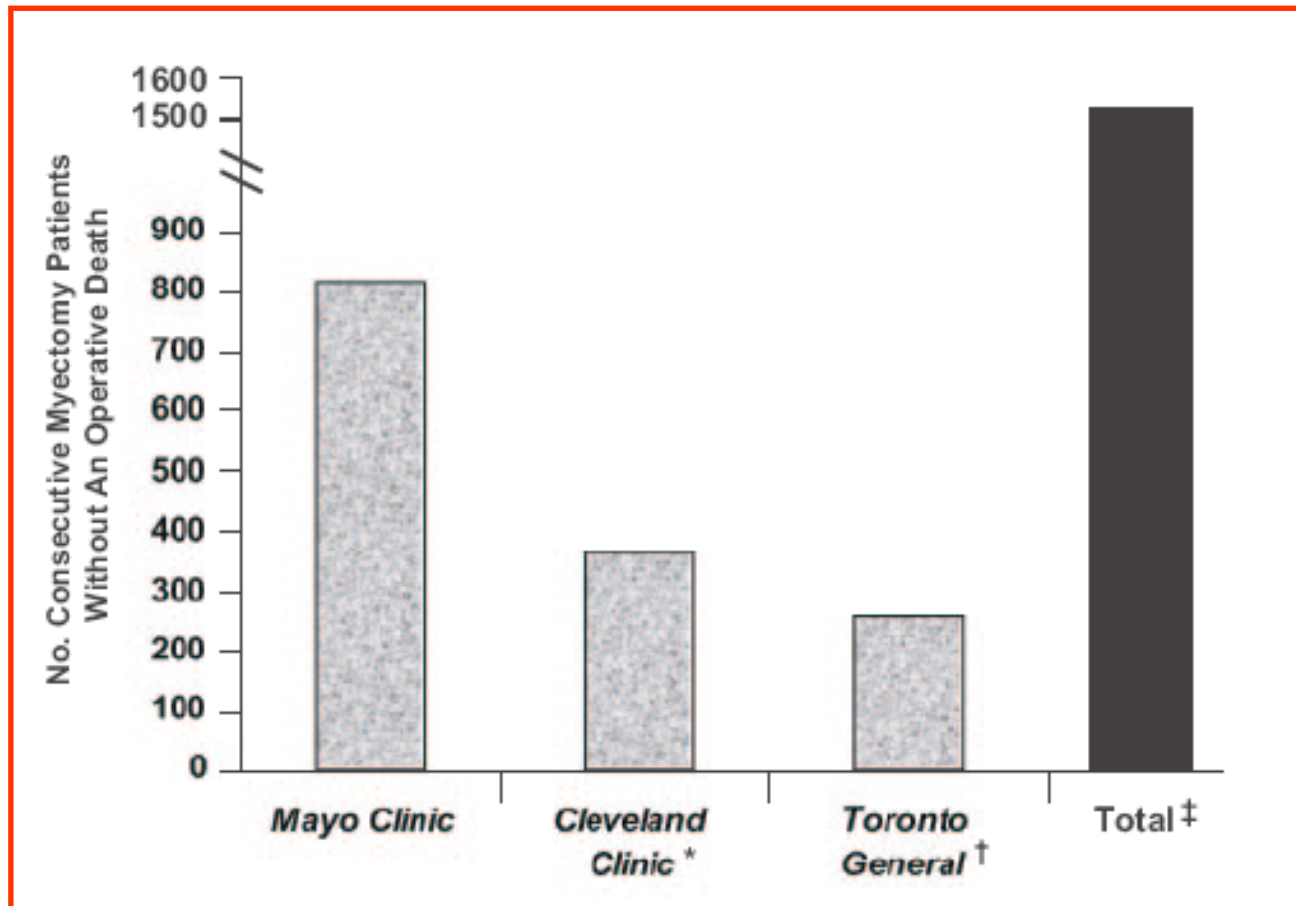


Surgical Management of HOCM

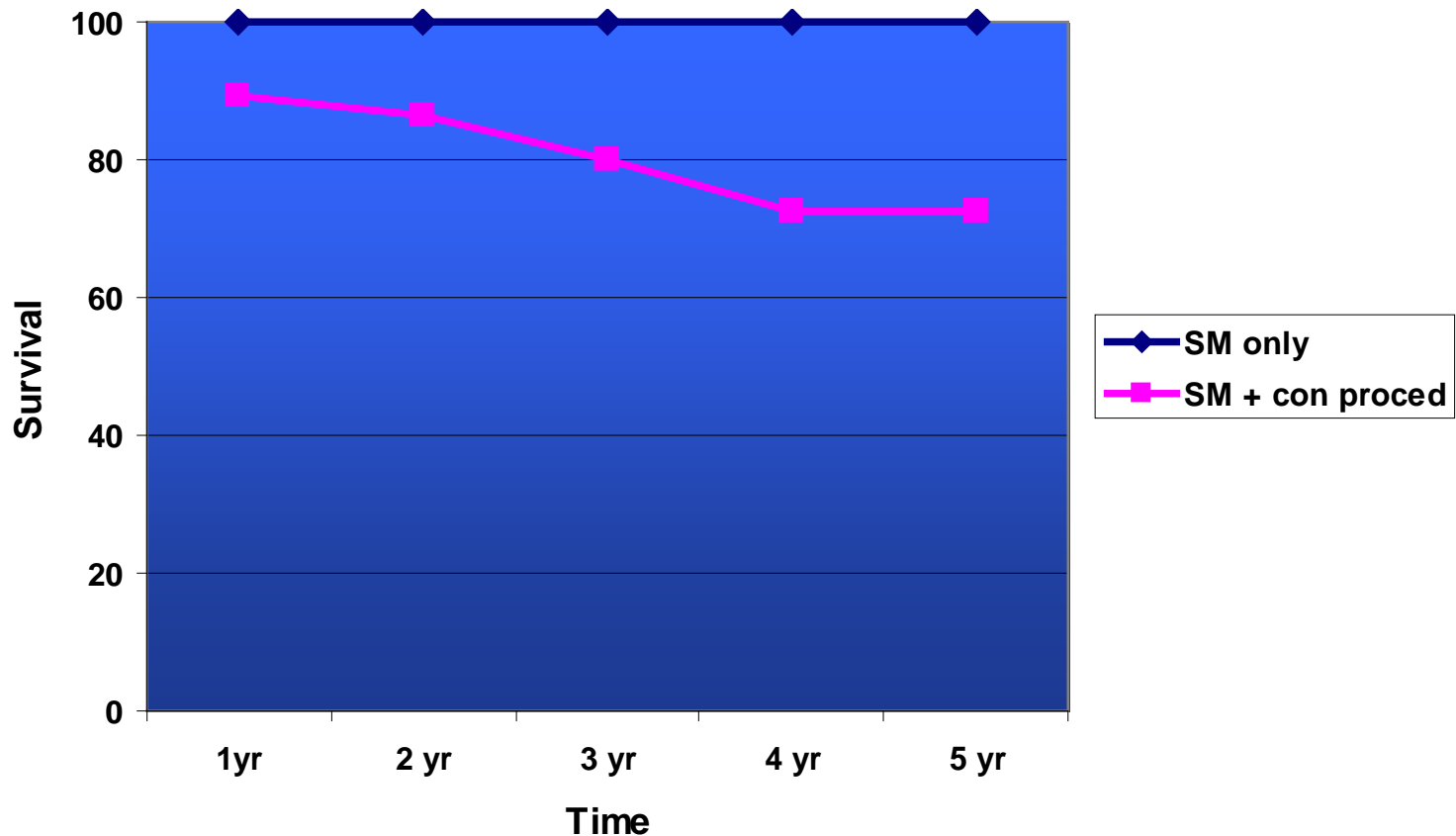
Advantages

- Symptom relief is known to persist long-term
- Reoperation is rarely necessary
- Direct visualization of outflow tract anatomy and associated mitral valve and papillary muscle abnormalities
- Can correct associated cardiac lesions
- No postoperative intramyocardial infarction/scar
- Very low operative mortality
- Long-term survival benefit

Consecutive Myectomies Without an Operative Death



Survival Following Septal Myectomy: Washington University Experience



Washington University Septal Myectomy Experience: Late Results (n=176)

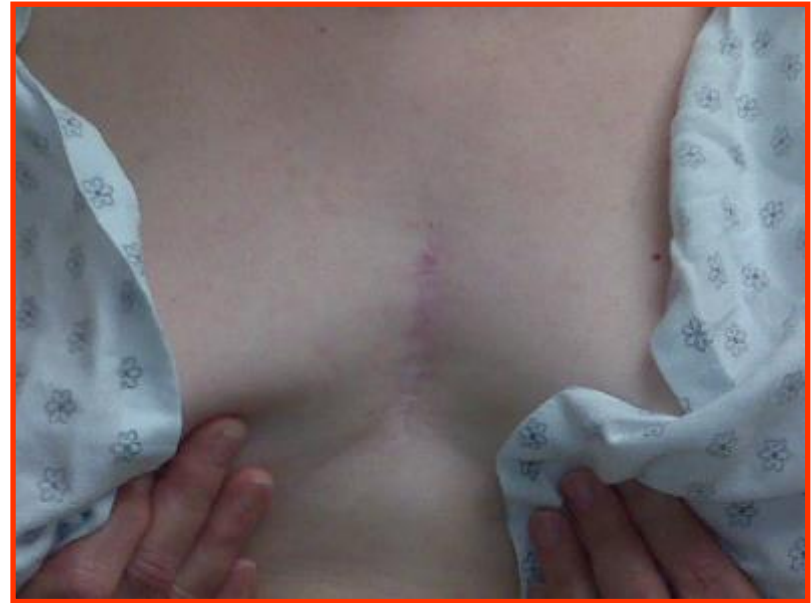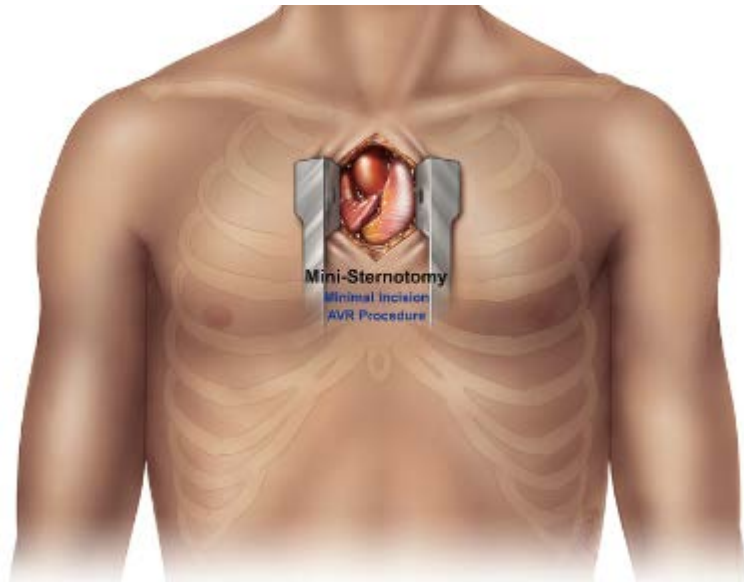
- Mean follow-up: 4.5 ± 7.1 years
- NYHA Class I,II: 89 %
- MR \leq 2+ : 87 %

Surgical Management of HOCM

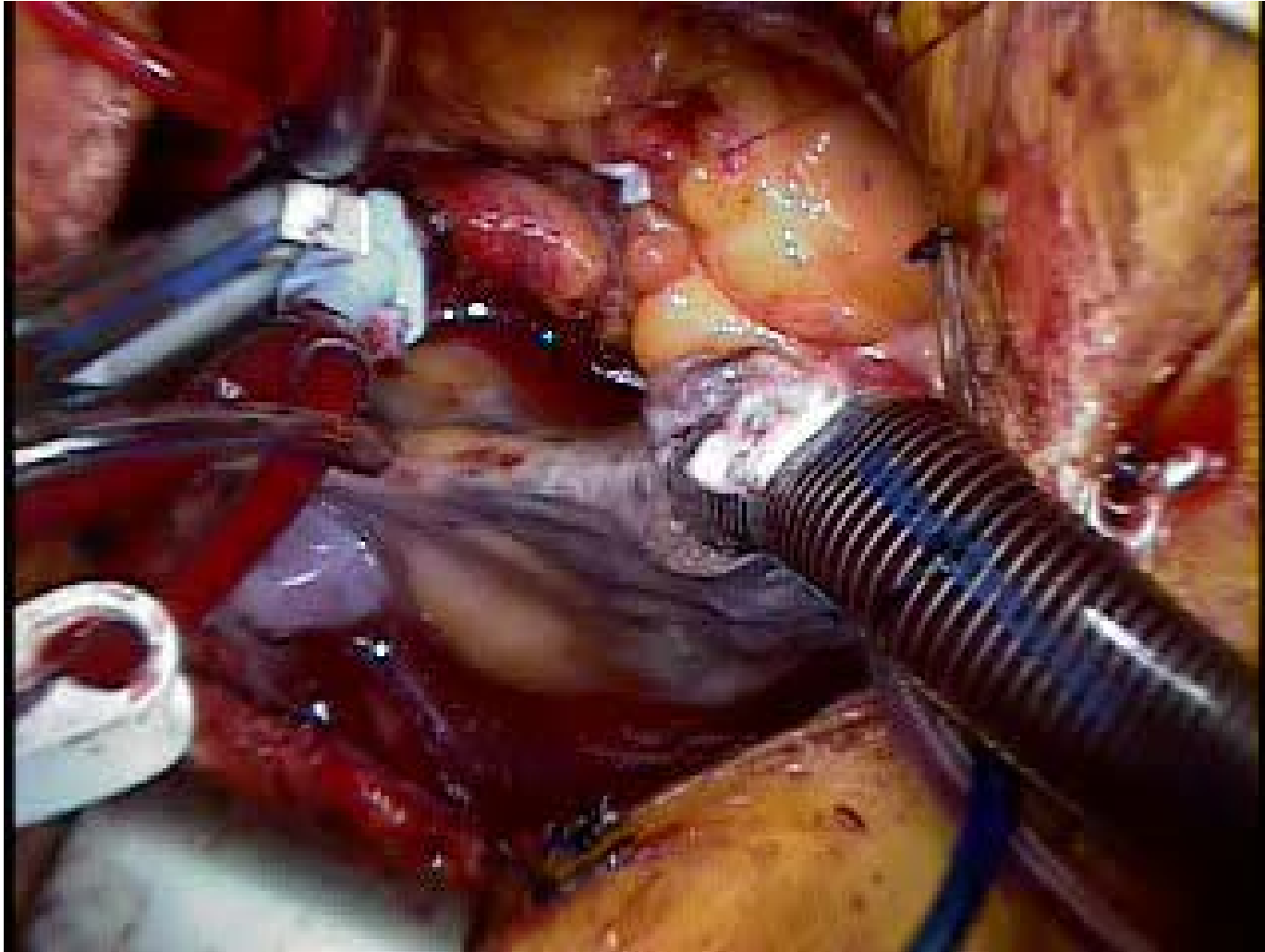
Disadvantages

- Requires experienced team to obtain excellent results
- Requires incision/cardiopulmonary bypass

Mini-Sternotomy Approach



Minimally Invasive Approach



Minimally Invasive Septal Myectomy: Washington University Experience

- 73 consecutive patients underwent isolated septal myectomy for HOCM from January 2004 – July 2014
 - 24 patients underwent full sternotomy
 - 49 patients underwent mini-sternotomy
 - Data entered prospectively into STS database
- Concomitant procedures were excluded
- Compared mini-sternotomy to full sternotomy

Preoperative Demographics

Variable	Full Sternotomy (n=24)	Mini-sternotomy (n=49)	<i>p</i> value
Male Gender	7 (29%)	25 (51%)	0.086
Mean age (yrs)	54.8 ± 12.4	49.8 ± 14.4	0.146
Body Mass Index (Kg/m ²)	34.5 ± 7	31.9 ± 6	0.091
Diabetes	3 (13%)	7 (14%)	1.00
Congestive Heart Failure	23 (96%)	47 (96%)	1.00
Creatinine	0.95 ± 0.28	0.96 ± 0.25	0.976
Previous valve surgery	1 (4%)	0	0.328
Previous ICD	3 (14%)	13 (29%)	0.229
Left Ventricular Ejection Fraction (%)	64.2 ± 10.3	64.8 ± 7	0.808
Mitral insufficiency (Mod/Sev)	12 (50%)	29 (59%)	0.74

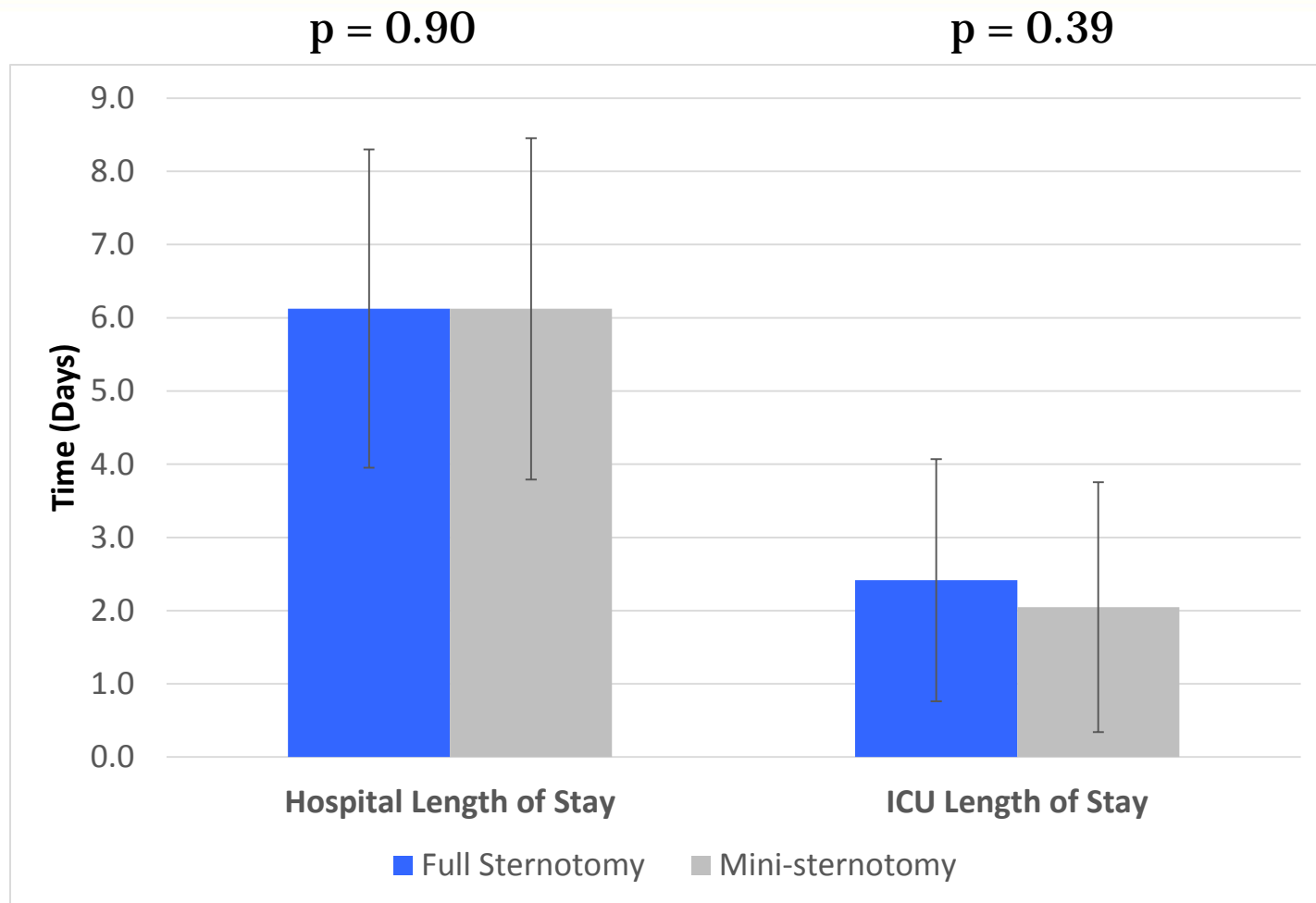
Operative Data

Variable	Full Sternotomy (n=24)	Mini-sternotomy (n=49)	<i>p</i> value
Perfusion time (min)	81.5 ± 15.8	86.0 ± 21	0.351
Cross clamp time (min)	38.7 ± 14	44.3 ± 12.9	0.100
Any intra-op blood product	12 (50%)	26 (53%)	1.00
Mean Intra-op RBCs (units)	0.91 ± 1.2	0.94 ± 1.3	0.944
Any post-op blood product	8 (40%)	13 (33%)	0.58
Mean post-op RBCs (units)	0.88 ± 1.4	0.55 ± 1.2	0.310

Postoperative Complications

Variable	Full Sternotomy (n=24)	Mini-sternotomy (n=49)	<i>p</i> value
Any post-op complication	10 (42%)	25 (51%)	0.469
CVA	0	1 (2%)	1.00
Heart block	1 (4%)	2 (4%)	1.00
Atrial Fibrillation	6 (25%)	12 (25%)	1.00
Pneumonia	0	0	--
Prolonged ventilation	1 (4%)	3 (6%)	1.00
Re-op bleeding	1 (4%)	2 (4%)	1.00
Superficial wound infection	0	1 (2%)	1.00
Post-op mortality	0	0	--

Results: Length of Stay



Minimally Invasive Septal Myectomy for the Treatment of Hypertrophic Obstructive Cardiomyopathy and Intrinsic Mitral Valve Disease

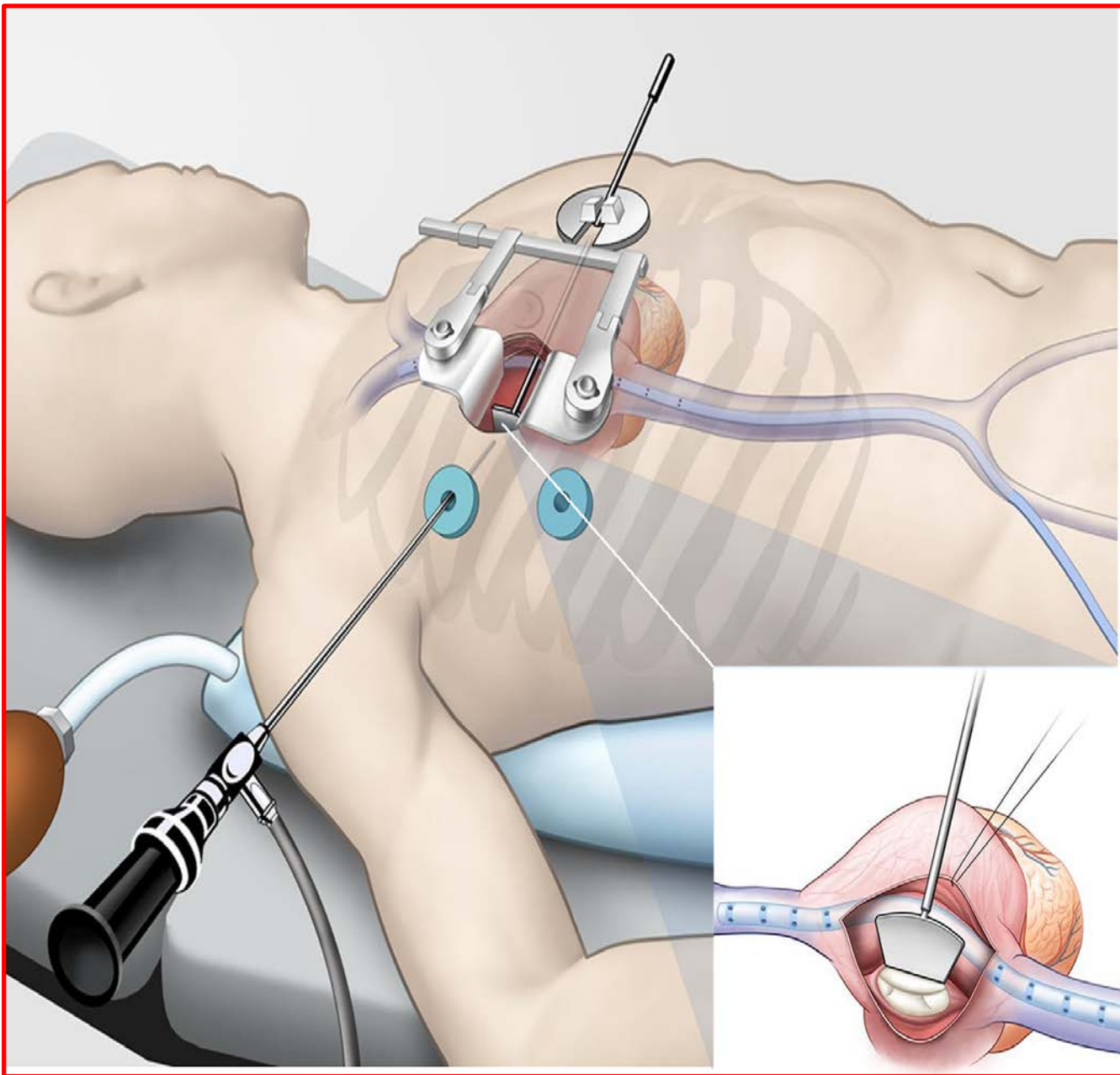
Daniyar Sh. Gilmanov, MD, Stefano Bevilacqua, MD, Marco Solinas, MD, Matteo Ferrarini, MD, Enkel Kallushi, MD, Filippo Santarelli, MD, Pier Andrea Farneti, MD, and Mattia Glauber, MD

Objective: Transaortic left ventricular septal myectomy described by Morrow is a classical procedure for the treatment of systolic anterior motion of the mitral apparatus associated with hypertrophic obstructive cardiomyopathy (HOCM). We aimed to review our results of transmitral septal myectomy and mitral valve repair/replacement in patients with intrinsic mitral valve disease associated with HOCM, operated on through a minimally invasive approach.

Methods: Between 2005 and 2014, 19 patients [7 men (37%); mean (SD) age, 69.4 (14.5) years] were treated with minimally invasive approach for degenerative mitral regurgitation and HOCM. Preoperative peak left ventricular outflow tract (LVOT) gradient was 66 (24) mm Hg. Severe mitral regurgitation was diagnosed in 16 cases (84%). New York Heart Association functional class III to IV heart failure was present in 13 patients (68%).

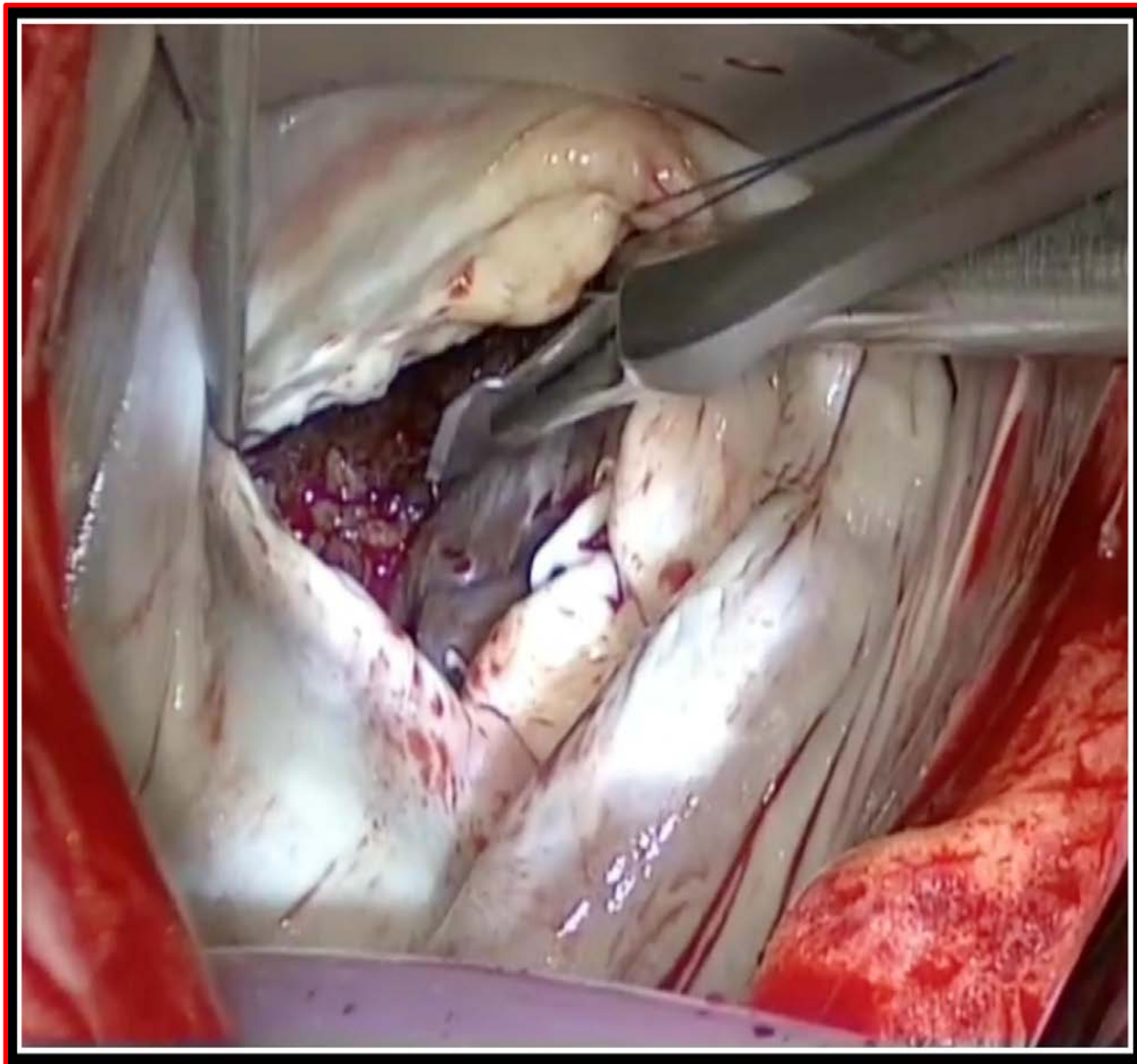
Results: Fifteen patients (79%) underwent mitral valve replacement, and four patients (21%) underwent mitral valve repair. Left ventricular outflow tract obstruction was corrected directly in all patients via the mitral valve with septal myectomy/myotomy, avoiding aortotomy in majority of the patients. No significant prolongation of extracorporeal circulation/aortic cross-clamping times was observed ($P = 0.41$ and $P = 0.67$, respectively) when compared with a similar population without HOCM. No iatrogenic ventricular septal defect developed in treated patients. No hospital mortality occurred. Resting LVOT gradient reduced at discharge to 13 (22) mm Hg ($P = 0.025$).

Conclusions: Transmitral left ventricular septal myectomy in patients with degenerative mitral valve disease is quite a simple, feasible, and effective technique and does not require aortotomy in most cases. It can be performed with low early mortality and satisfactory resolution of LVOT obstruction in a minimally invasive setting.



Soft Tissue Retractor



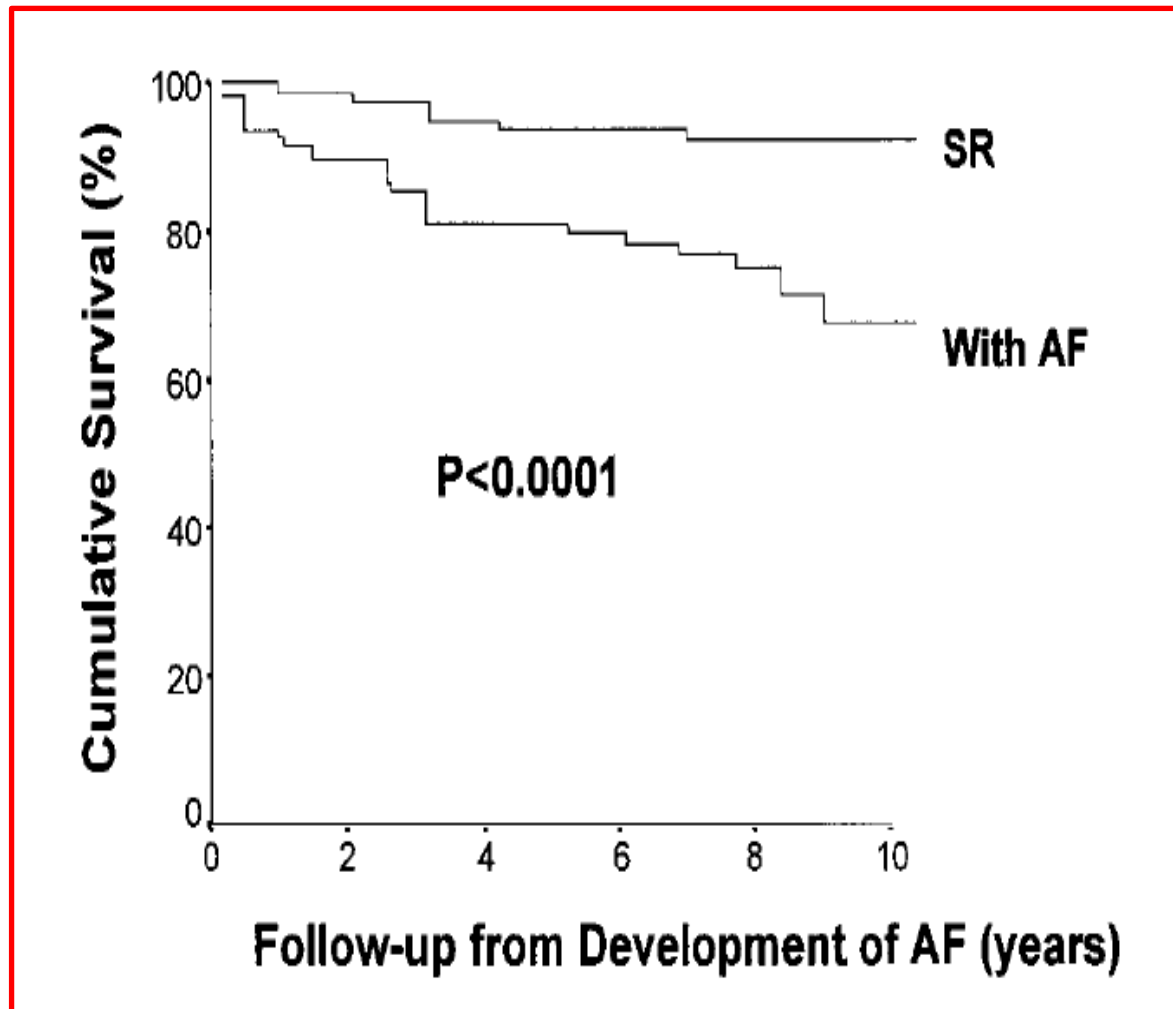


New Approaches to the Surgical Management of HOCM

- Minimally invasive approaches for septal myectomy are feasible and have the potential to further reduce surgical trauma.
- Early experience suggests that in experienced hands, minimally invasive incisions can achieve the same excellent results as a full sternotomy.

New Approaches to the Surgical Management of HOCM: Concomitant Atrial Fibrillation

- Atrial fibrillation is a common sequela of HCM, with an estimated 20% lifetime risk, and a prevalence as high as 40% in patients over 70 y.o.
- Patients with AF have a higher late mortality, with a hazard ratio of 1.48, but the presence of AF does not increase the occurrence of sudden cardiac death.

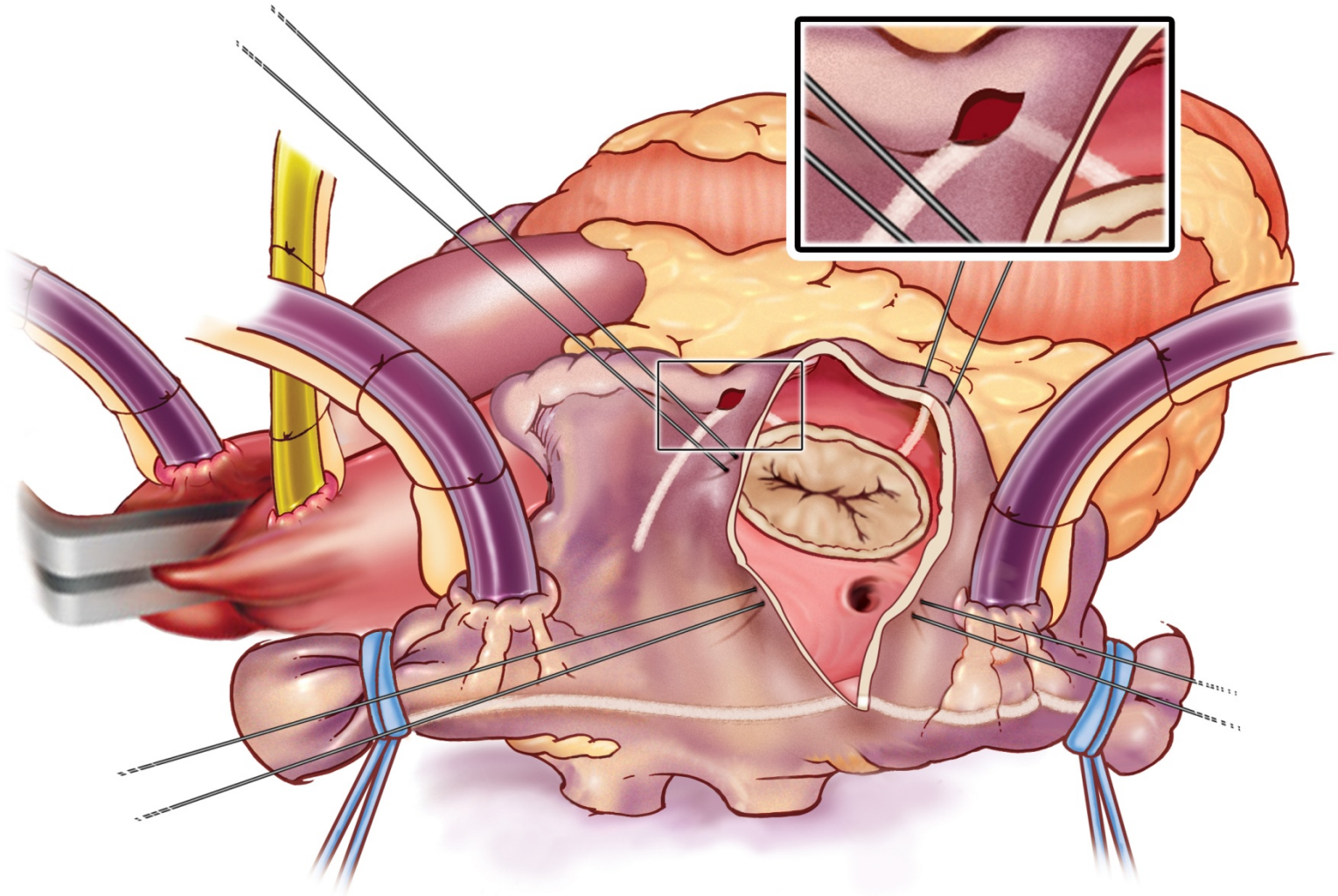


HOCM and Atrial Fibrillation: The Washington University Approach

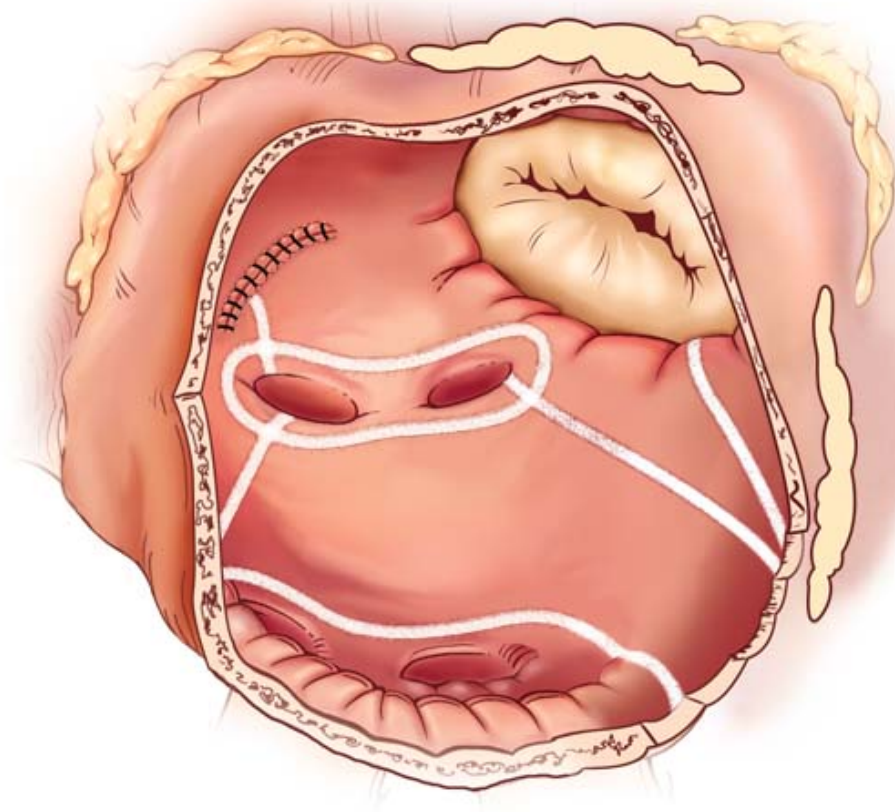
- Aggressive approach to surgical ablation in these patients.
- They are usually very symptomatic, since the loss of atrial kick in patients with LV diastolic dysfunction is poorly tolerated.
- Our preferred strategy is a biatrial Cox-Maze procedure.

“For severely symptomatic patients with outflow obstruction and AF, combining myectomy with the Maze procedure has been suggested, although the efficacy of this practice is unknown.”

Right Atrial Lesions of the Cox Maze IV



Left Atrial Lesions of the Cox Maze IV



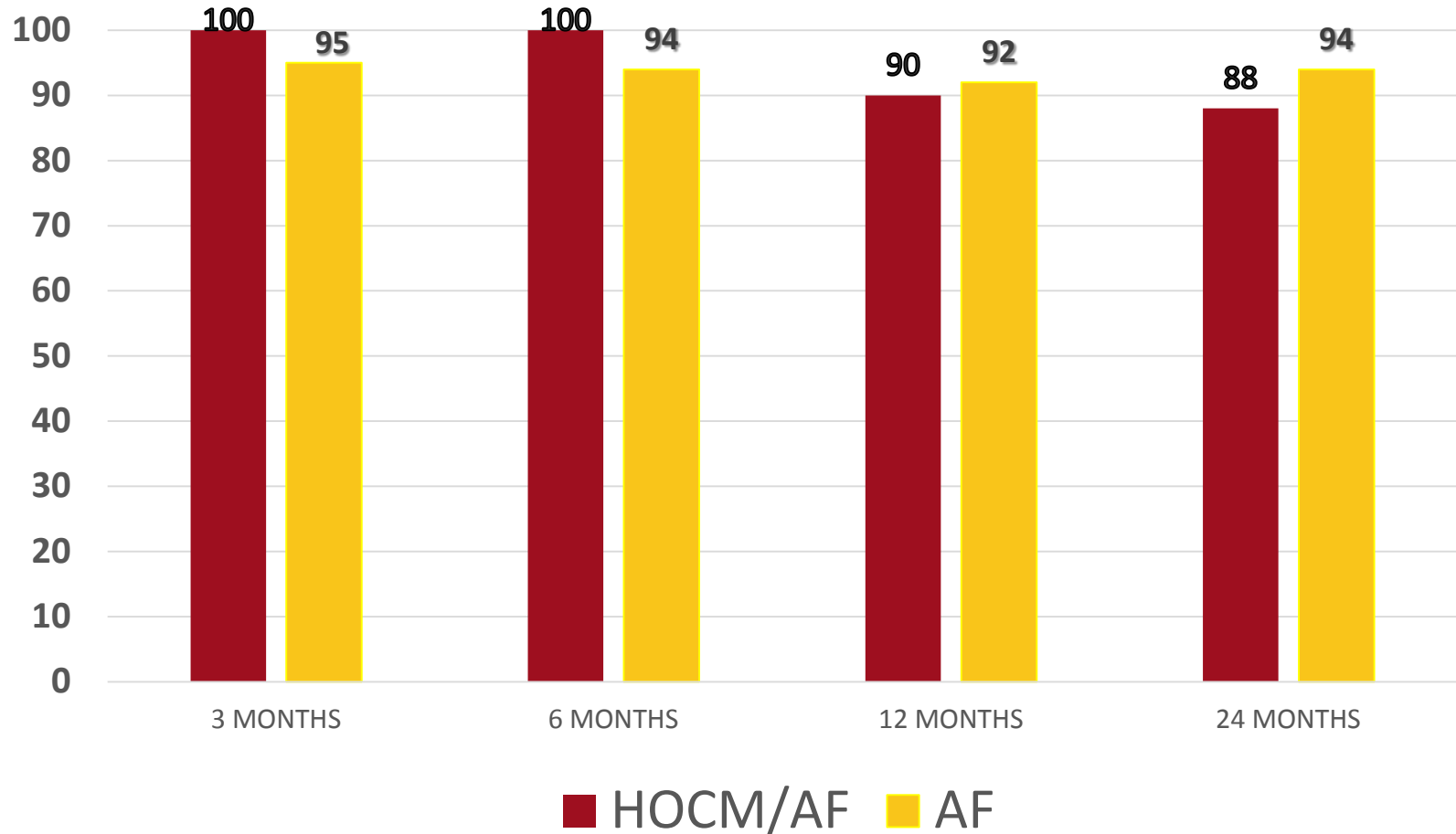
HOCM and AF: Washington University Experience

- 27 consecutive patients with HOCM/AF underwent a combined septal myectomy/Maze procedure.
- 74% (20/27) NHYA class III-IV
- 70%(19/27) had paroxysmal AF
- AF Duration: 49.0 ± 66.9 months
- LA Diameter: 5.23 ± 1.0 cms.

HOCM and AF: Washington University Experience

- 96% of patients were available for follow-up at a mean of 4.7 ± 3.1 years.
- Compared to isolated septal myectomy, there was no increase in major complication rate or mortality.
- Late results were excellent.

Freedom From Atrial Arrhythmias



New Approaches to the Surgical Management of HOCM:

Approaches to address residual mitral regurgitation

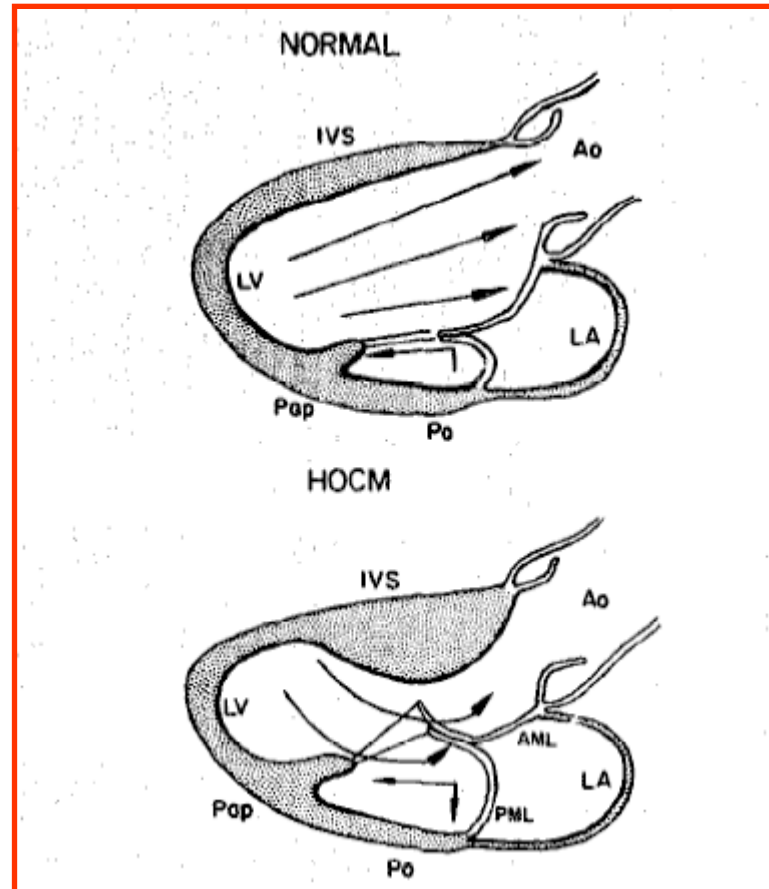
- A properly performed septal myectomy almost always corrects the SAM and MR.
- Concomitant mitral surgery is rarely needed (2% of patients in Mayo experience).
 - Nikamura, RA and Schaff, HV. J Am Coll Cardiol 2015;66:1697-1699

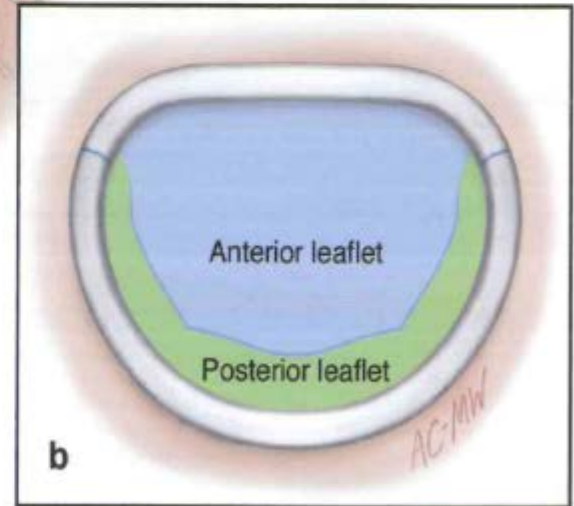
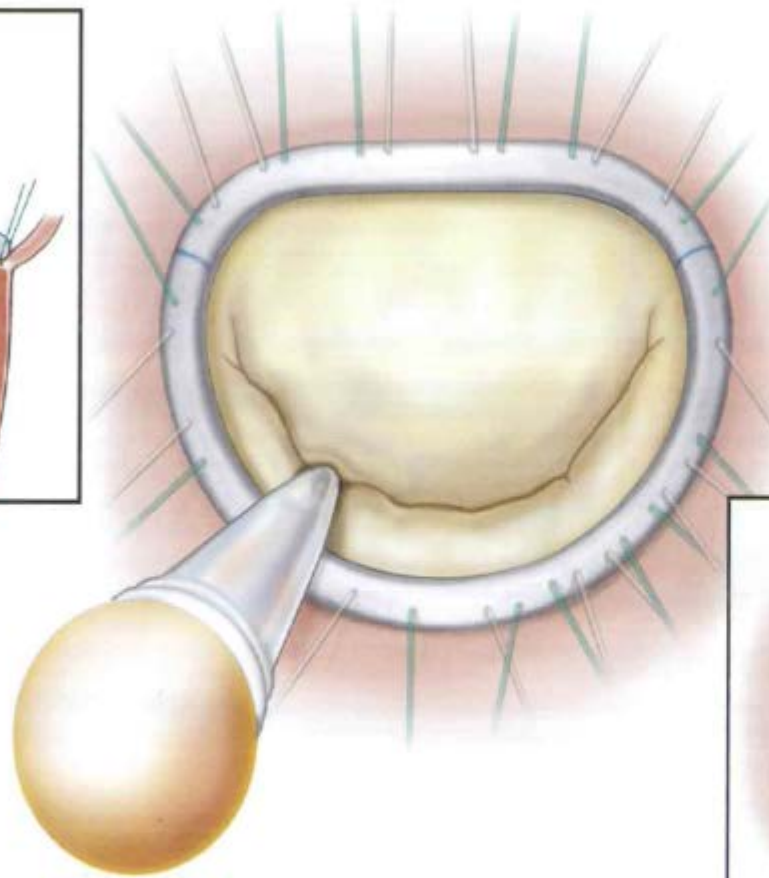
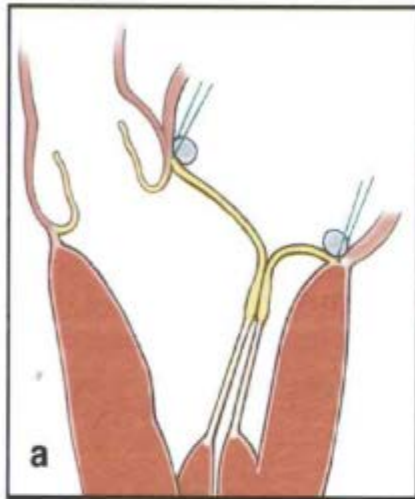
New Approaches to the Surgical Management of HOCM:

Approaches to address residual mitral regurgitation

- In patients with organic mitral pathology unrelated to HOCM physiology, mitral repair requires careful attention and planning.
- We favor leaflet patching and/or an Alfieri stitch to prevent SAM.

Hypertrophic Obstructive Cardiomyopathy: Hemodynamic alterations





Initial Results of Combined Anterior Mitral Leaflet Extension and Myectomy in Patients With Obstructive Hypertrophic Cardiomyopathy

MARCEL J. KOFFLARD, MD, LEX A. VAN HERWERDEN, MD, PhD, DAVID J. WALDSTEIN, MD,*
PETER RUYGROK, MD, ERIC BOERSMA, MSc, MEINDERT A. TAAMS, MD, PhD,
FOLKERT J. TEN CATE, MD, PhD, FACC

Rotterdam, The Netherlands and Chicago, Illinois

Objectives. The purpose of this study was to describe the clinical and functional results of combined anterior mitral leaflet extension and myectomy in patients with hypertrophic obstructive cardiomyopathy.

Background. Septal myectomy is the most commonly performed surgical procedure in patients with hypertrophic cardiomyopathy and left ventricular outflow tract obstruction. Because of the role of the mitral valve in creating the outflow tract gradient, mitral valve replacement or plication is performed in selected cases in combination with myectomy, often with better hemodynamic results than those of myectomy alone. Mitral valve leaflet extension, in which a glutaraldehyde-preserved autologous pericardial patch is used to enlarge the mitral valve along its horizontal axis, is a novel surgical approach in patients with hypertrophic obstructive cardiomyopathy.

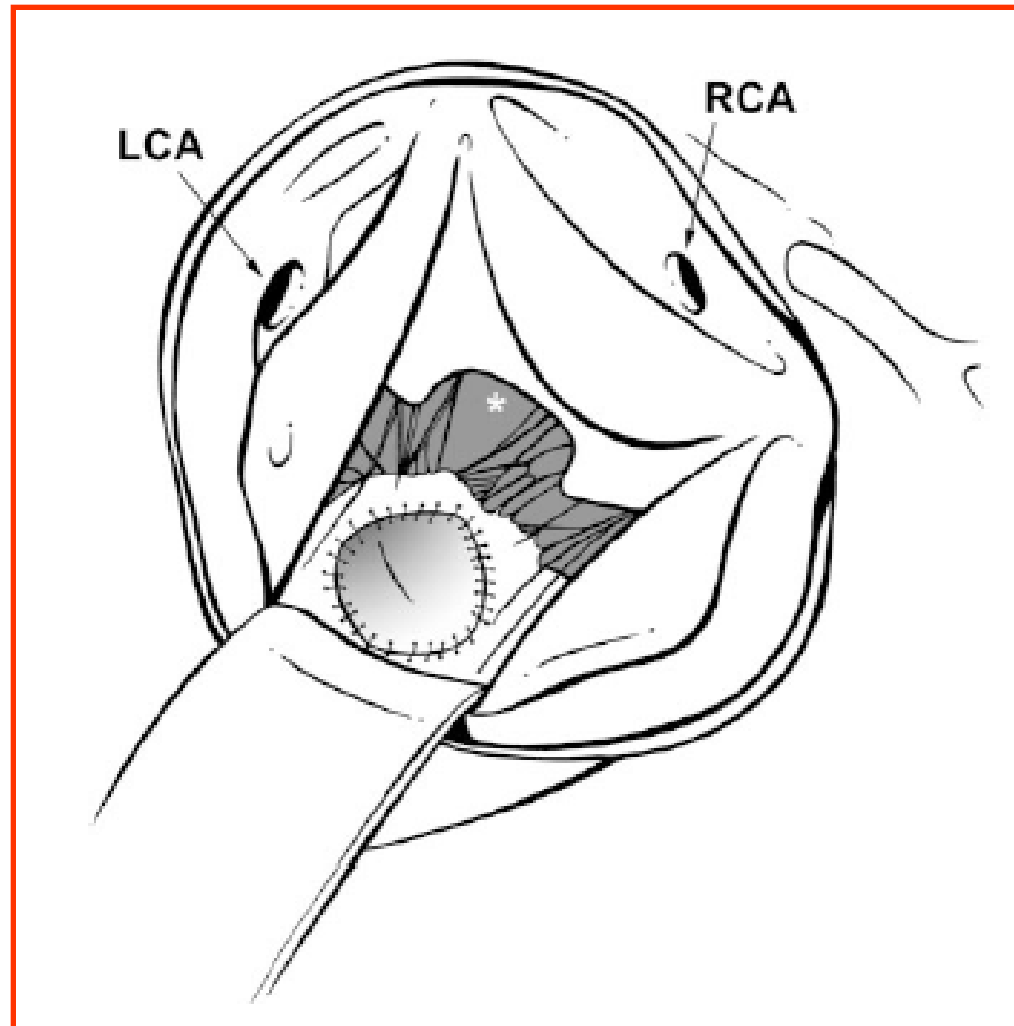
Methods. Eight patients with hypertrophic obstructive cardiomyopathy were treated with mitral leaflet extension and myectomy. Preoperative and postoperative data (New York Heart Association functional class, number of drugs prescribed, width of the interventricular septum, severity of mitral valve regurgitation,

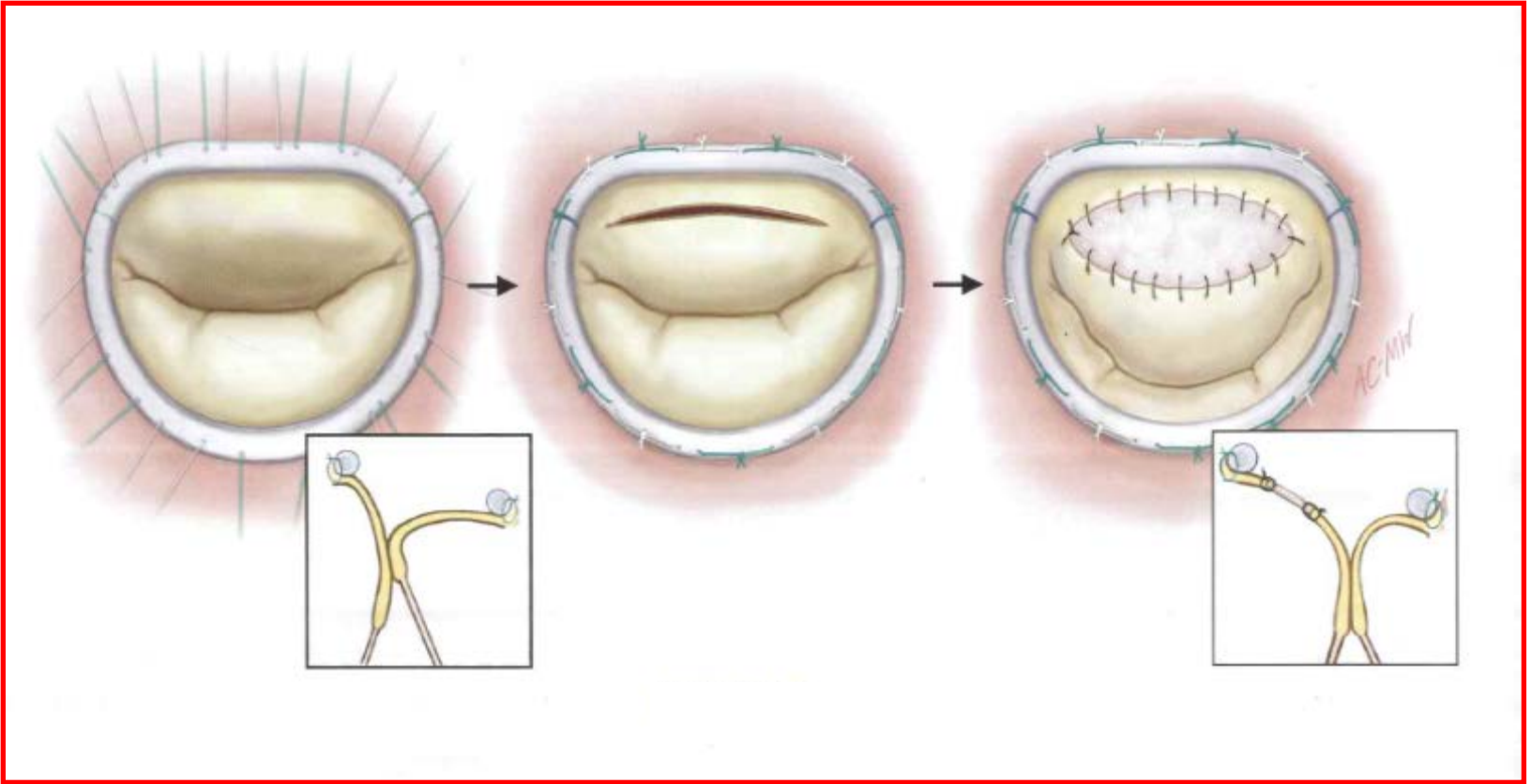
severity of systolic anterior motion of the mitral valve and outflow tract gradient) were compared with those of 12 patients undergoing myectomy alone.

Results. Preoperative evaluation demonstrated that mitral regurgitation and systolic anterior motion of the mitral valve were more severe in the group undergoing mitral valve extension ($p < 0.001$ and $p < 0.05$, respectively). There were no deaths associated with either surgical procedure. Two patients, both treated by myectomy alone, died during the follow-up period. Postoperatively, patients treated with mitral valve extension had less mitral regurgitation ($p < 0.005$), less residual systolic anterior motion ($p < 0.01$), greater improvement in functional class ($p = 0.05$) and greater reduction in the number of drugs ($p < 0.005$) and in septal thickness ($p < 0.05$).

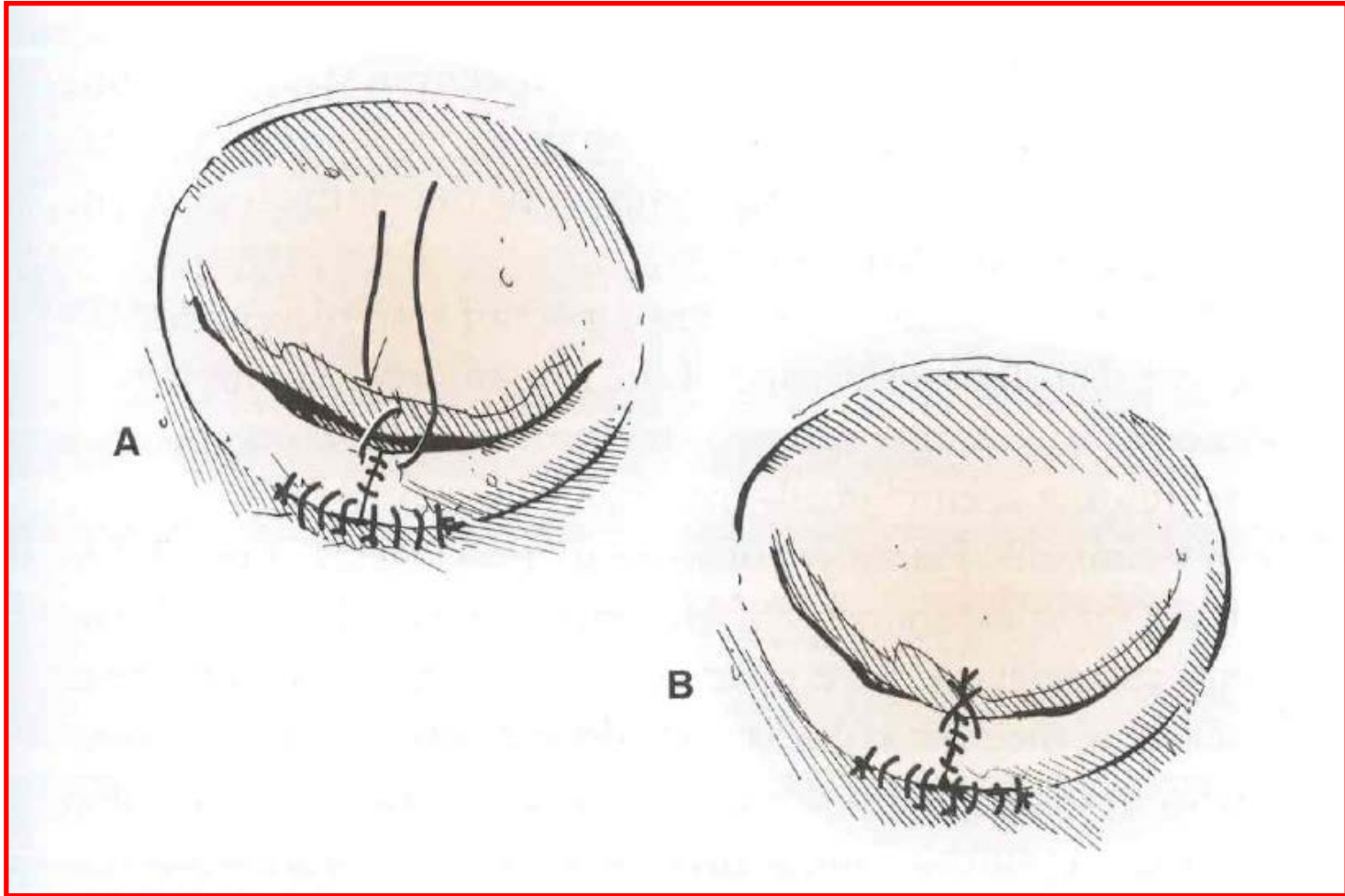
Conclusions. Mitral leaflet extension in combination with myectomy is a promising new surgical approach that may provide superior results to those of myectomy alone. Further studies are needed to determine the clinical value of this procedure.

(J Am Coll Cardiol 1996;28:197-202)





Alfieri Stitch



Transaortic Chordal Cutting

Mitral Valve Repair for Obstructive Hypertrophic Cardiomyopathy With Mild Septal Hypertrophy



Paolo Ferrazzi, MD,* Paolo Spirito, MD,† Attilio Iacovoni, MD,‡ Alice Calabrese, MD,‡ Katrin Migliorati, PhD,* Caterina Simon, MD,§ Samuele Pentiricci, MD,§ Daniele Poggio, MD,* Massimiliano Grillo, MD,* Pietro Amigoni, MD,* Maria Iascone, PhD,|| Andrea Mortara, MD,* Barry J. Maron, MD,¶ Michele Senni, MD,‡ Paolo Bruzzi, PhD, MD#

ABSTRACT

BACKGROUND In severely symptomatic patients with obstructive hypertrophic cardiomyopathy (HCM) and mild septal hypertrophy, mitral valve (MV) abnormalities may play an important role in MV displacement into the left ventricular (LV) outflow tract. Therefore, isolated myectomy may not relieve outflow obstruction and symptoms, and MV replacement is often the surgical alternative.

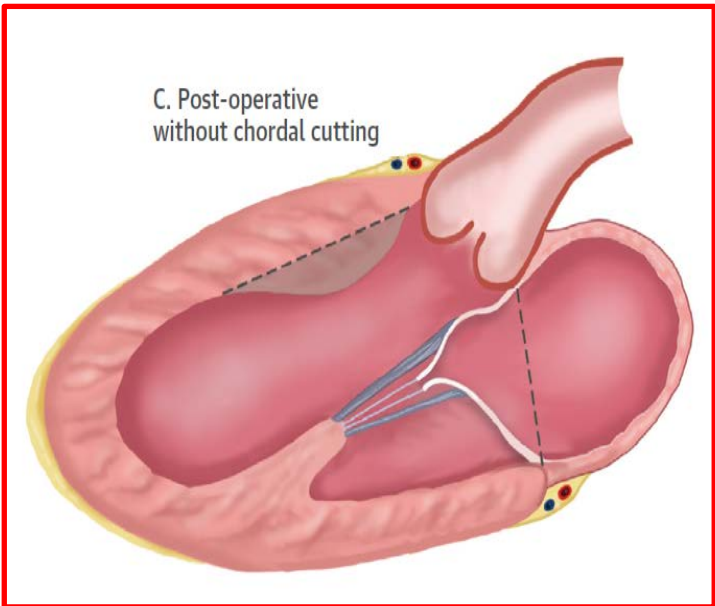
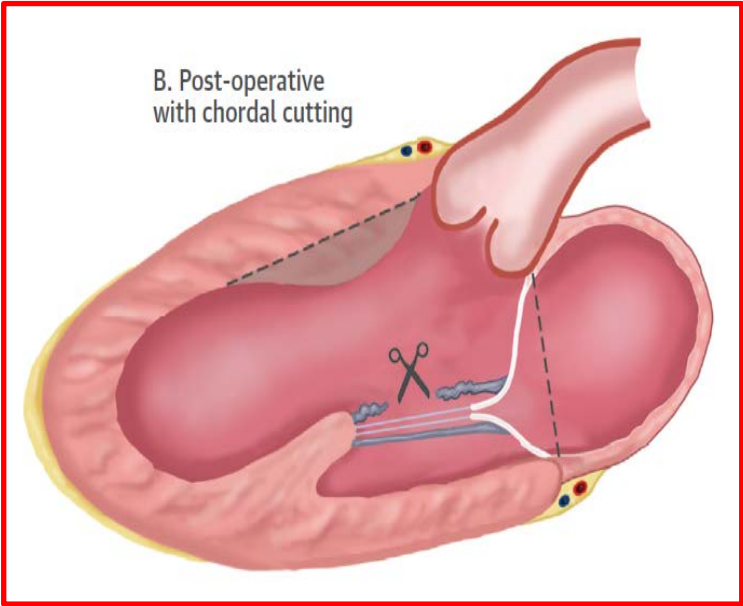
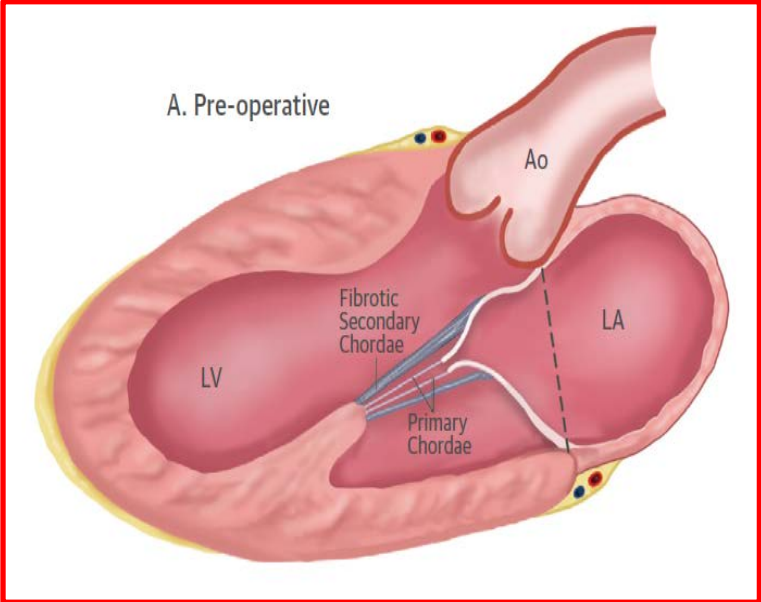
OBJECTIVES This study sought to assess the clinical and hemodynamic results of cutting thickened secondary MV chordae combined with a shallow septal muscular resection in severely symptomatic patients with obstructive HCM and mild septal hypertrophy.

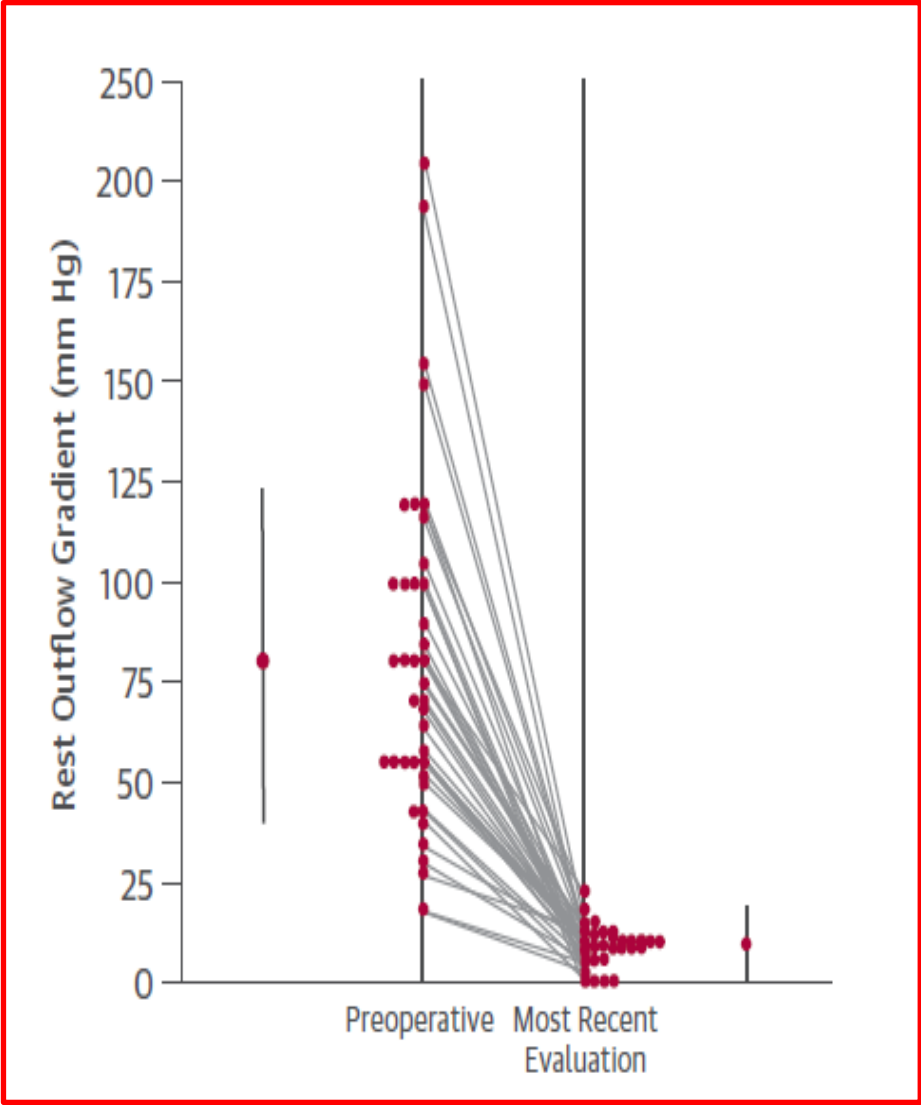
METHODS Clinical features were compared before surgery and at most recent clinical evaluation in 39 consecutive patients with obstructive HCM.

RESULTS Over a 23 ± 2 months follow-up, New York Heart Association functional class decreased from 2.9 ± 0.5 pre-operatively to 1.1 ± 1.1 post-operatively ($p < 0.001$), with no patient in class III at most recent evaluation. The resting outflow gradient decreased from 82 ± 43 mm Hg to 9 ± 5 mm Hg ($p < 0.001$) and septal thickness decreased from 17 ± 1 mm to 14 ± 2 mm ($p < 0.001$). No patient had MV prolapse or flail and 1 had residual moderate-to-severe MV regurgitation at most recent evaluation. MV geometry before and after surgery was compared with that of 25 consecutive patients with similar clinical profile and septal thickness that underwent isolated myectomy. After adjustment for differences in pre-operative values between the groups, the post-operative anterior MV leaflet-annulus ratio was 17% greater and tenting area 24% smaller in patients with chordal cutting, indicating that MV apparatus had moved to a more normal posterior position within the LV cavity, preventing MV systolic displacement into the outflow tract and outflow obstruction.

CONCLUSIONS This procedure relieves heart failure symptoms, abolishes LV outflow gradient, and avoids MV replacement in patients with obstructive HCM and mild septal thickness. (J Am Coll Cardiol 2015;66:1687-96)

© 2015 by the American College of Cardiology Foundation.





New Approaches to the Surgical Management of HOCM:

Conclusions

- Surgical septal myectomy is the gold standard for the treatment of HOCM with excellent late symptom and gradient improvement. Minimally invasive approaches may continue to limit morbidity.
- Surgery offers the advantage of being able to address other cardiac abnormalities including AF, associated mitral pathology, CAD, and papillary muscle and chordal anomalies which can exacerbate the LVOTO.

Heart & Vascular Center



NATIONAL LEADERS IN MEDICINE